

Hair Growth Stimulation in Testosterone-Induced Alopecic Mice: A Comparative Study between Topical Clove oil 10% Topical Minoxidil 5%

Banan A. Mohammed*¹, Huda I. Qasim¹

¹Department of Pharmacology, College of Medicine, University of Baghdad, Baghdad, Iraq.



©2025 The Author(s). Published by the College of Medicine, University of Baghdad. This open-access article is distributed under the terms of the Creative Commons Attribution 4.0 International License, which permits unrestricted use, distribution, and reproduction in any medium, provided the original work is properly cited.

Abstract:

Background: Hair follicle degradation characterizes androgenic alopecia (AGA). Deterioration shortens anagen and lengthens telogen, turning terminal hairs into vellus hairs. Males and females have this prevalent sickness. Antibacterial, anti-inflammatory, and antioxidant *Syzygium aromaticum* may treat it.

Objectives: To investigate *Syzygium aromaticum* as a hair growth booster in testosterone-induced alopecia as an alternative to allopathic treatments with fewer side effects.

Methods: A controlled experimental animal study at College of Pharmacy/ University of Baghdad was conducted from November 2022 to December 2024. Male BALB/c mice weighing 25–30 grams and aged 8–12 weeks were used. Alopecia treatment often uses 5% minoxidil (0.1 mL). Alopecia was treated with 10% *Syzygium aromaticum* oil (0.8 mL). A 5% testosterone solution (100 µL) caused baldness in mice. Four groups of eight animals were randomly assigned: No treatment was given to Group I (Negative Control) after dorsal hair shaving. Group II (Alopecia Control) received only 5% testosterone. Group III (Minoxidil Group) received 5% testosterone and 5% minoxidil. Group IV (Clove Oil Group) received 5% testosterone and 10% *Syzygium aromaticum* oil.

Results: In Group II, testosterone-induced alopecia caused significant decreases in Anagen/Telogen A/T ratio (1.12 ± 0.09) and follicular density (4.8 ± 0.5 follicles/field) compared to the control group (Group I: 3.91 ± 0.24 ; 10.2 ± 0.7). Compared to the induced group, 5% minoxidil treatment (Group III) significantly increased A/T ratio (3.56 ± 0.20) and follicular density (9.5 ± 0.6). Group IV clove oil treatment showed significant A/T ratio improvement (3.32 ± 0.18), but comparable follicular density (8.8 ± 0.9) to minoxidil was insignificant. Histology corroborated these findings, showing that minoxidil and clove oil groups had higher follicle counts and better follicular architecture, with the former having more clustered and the latter more horizontal.

Conclusion: Androgenic alopecia treatments may be replaced by *Syzygium aromaticum*. It needs human trials to prove its efficacy and safety.

Keywords: Androgenic alopecia; Hair; Minoxidil; *Syzygium aromaticum*; Testosterone.

Received: Oct. 2024

Revised: April, 2025

Accepted: May, 2025

Published Online: May, 2025

Introduction:

Alopecia is a concerning dermatological disorder characterized by the loss of hair. Although hair has minimal physiological function, hair loss can be psychologically traumatic and adversely affect the individual's self-esteem (1,2). It surpasses demographic, racial economic, age, and gender boundaries. The origin of hair loss remains ambiguous; however, it has been ascribed to several potential variables, including hormonal imbalance, thyroid dysfunction, chemotherapy, impaired liver and kidney function, and hereditary susceptibility. Lupus erythematosus, parturition, thermal injury, vitiligo, mycotic infection, diabetes mellitus, rheumatoid arthritis, autoimmune disorders, psychological trauma, and excessive application of chemicals to hair, including dyes, bleaches, and

blow drying can cause hair loss (3,4).. In androgenic alopecia (AGA), testosterone can adversely affect hair follicles by being transformed into DHT by the enzyme 5 α -reductase type II. Dihydrotestosterone (DHT) exhibits greater potency than testosterone due to its superior binding affinity to androgen receptors (AR) inside the dermal papilla cells of hair follicles. The DHT-AR complex can stimulate the generation of reactive oxygen species and inflammatory cytokines (5,6,7). Only minoxidil (MXD) and finasteride are FDA approved, not sanctioned for androgenic alopecia (AGA) treatment (8).

Clove essential oil is extracted from the desiccated bud part of *Syzygium aromaticum* (L.) (Family *Myrtaceae*). It contains many metabolites including: Ester, aldehyde, ketone, alcohol, and terpenic hydrocarbons (sesquiterpenes and monoterpenes). Clove oil possesses anti-inflammatory, antioxidant,

*Corresponding email:
banan.abd2106p@comed.uobaghdad.edu.iq

antifungal, antiviral, antimicrobial, and antibacterial effects(9,10). The study aimed to examine the *Syzygium aromaticum* as a promoter of hair development in testosterone-induced alopecia as an alternative to allopathic treatments with less adverse effects.

Materials and Methods

Laboratory Animals: The research was conducted at the College of Pharmacy, University of Baghdad, from November 2022 to December 2024. Male BALB/c mice with ages 8 to 12 weeks were used for the study. The animals were kept on a cycle of 12-hour light and 12-hour dark at a controlled temperature of $22\pm 2^{\circ}\text{C}$ and 45% humidity. Experiments were done in accordance with The National Institutes of Health and the American Veterinary Medical Association (AVMA) (11), after the approval of the experimental procedures by the Committee of the College of Medicine, University of Baghdad (protocol number 03-21).

Pharmaceuticals and Chemical Substances

Ketamine 10% and Xylazine 2% (Alfasan/Woerden-Holland Aldawa Co, Iraq), Paraffin wax (Al-Asera Co., Iraq), Minoxidil solution 5% (Regenepure, USA), Testosterone solution 5% (Liba, China).

Plant preparation: The bud parts of *Syzygium aromaticum* from Iraq were utilized to extract its essential oil. They were identified by the Iraqi Natural History Research Center and Museum, Plant and Environmental Department on March 17, 2025. The hydro-distillation extraction was performed in a round-bottom flask utilizing Clevenger equipment, with a water-to-dried herb ratio of 10:1. A total of 15

g of *Syzygium aromaticum* L. was employed for hydro-distillation at 100°C for a duration of 4 hours. The resulting essential oil was dehydrated with anhydrous sodium sulfate and stored at 4°C in a refrigerator until testing could be performed (12).

Phytochemical Examination: The extract thereafter underwent several phytochemical testing for the identification of distinct phytochemical components. The plant extract was then analyzed for significant phytochemicals that may contribute to its effects, including flavonoids, total alkaloids, steroids, triterpenoids, and other compounds (12).

Protocol of treatment: The mice were randomly allocated into four groups ($n = 8$). To create a baseline for comparison and isolate the treatment effects, the control group (Group 1) was given sterilized water. Three experimental groups received a daily topical testosterone solution at a 5% concentration, delivered in doses of $100\text{ }\mu\text{L}$ for 60 consecutive days (13).

Group 2 (Testosterone-induced group): Received a daily topical dose of 5% testosterone solution ($100\text{ }\mu\text{L}$) for 60 days, without any further treatment. Group 3 (Minoxidil-treated group): Received a daily topical dosage of 0.1 mL of 5% minoxidil solution one hour after testosterone treatment for 60 days (14).

Group 4 (Clove oil-treated group): Received a daily topical application of 0.8 mL of 10% *Syzygium aromaticum* (clove) oil onehour post-testosterone application for 60 days (15).

All interventions were administered to the depilated dorsal epidermis of the mice. Figure 1 depicts the experimental flow chart for the four study groups.

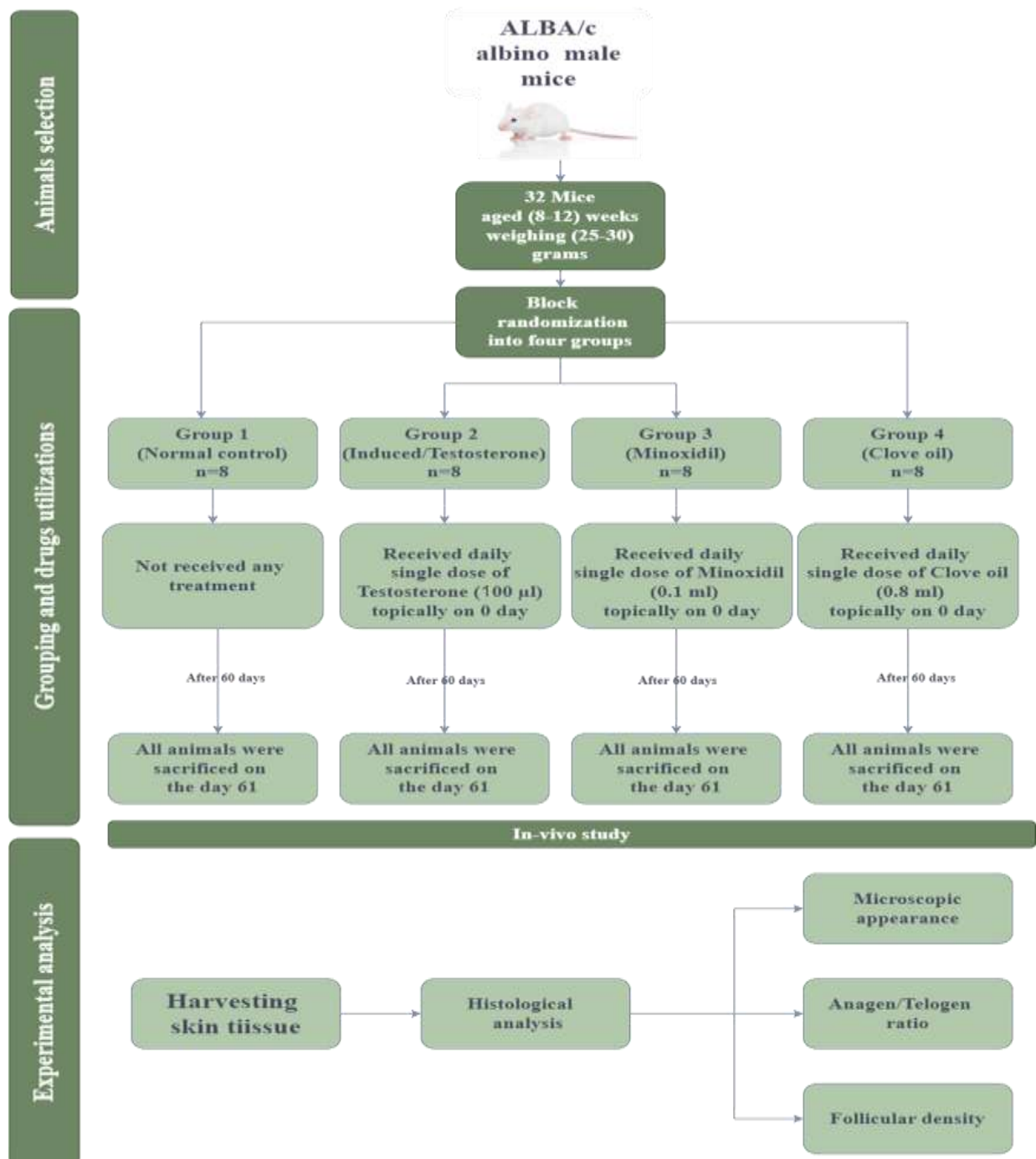


Figure 1: The study flow diagram

Histopathological analysis: The skin histopathological study encompassed essential procedures: 1) Fixation of skin specimens in 10% buffered formalin for 24 hours to maintain tissue integrity; 2) Paraffin embedding to furnish support for the tissue during sectioning; 3) Sample Maintenance, wherein all samples were preserved at ambient temperature in a dry, dark environment to maintain tissue integrity until further examination; 4) Sectioning the implanted tissue into thin slices; 5) Staining the slices with hematoxylin and eosin (H&E) to accentuate cellular features; 6) Microscopic examination to evaluate follicular

density and the anagen-to-telogen ratio utilizing an ocular micrometer; and 7) Image capture of the stained slides for record(16,17,18).

Quantitative assessment: Figures 3B and 3C present the data as mean \pm standard deviation (SD). The Kruskal-Wallis test and the Dunn test were used to compare the groups. P-values < 0.05 represent the significant level (< 0.01 , 0.001 , and 0.0001) Data analysis was performed with SPSS 29.0, while the GraphPad Prism 8.0. was used to generate graphs and figures.

Results

This study found that clove oil's pharmacological effect is linked to its many phytochemicals, which are listed in Table 1.

Table 1: Examination of Phytochemical Analysis in clove oil, the mark "+" denotes the presence of phytoconstituents

Test	Reagents	Changes	Mark
Flavonoids Test	Sulfuric acid + ammonia	Yellowish tint that dissipated upon standing	+
Tannins Test	Ferric chloride	A blue-green tint emerged	+
Alkaloids Test	Mayer's reagent	White deposits	+
Terpenoids Test	Chloroform + sulfuric acid	Reddish hue	+
Sterols Test	Salkowski test	Reddish tint	+
Saponin Test	Sodium bicarbonate	Foam formation	+

Clove oil enhances the Anagen/Telogen ratio in testosterone-induced androgenic alopecia: There was a significant decrease in the anagen/telogen ratio in the induced group compared to the normal group ($P = 0.000$); conversely, the dorsal skin anagen/telogen ratio of animals treated with

minoxidil (standard treatment) showed a significant increase compared to the induced group ($P = 0.000$). Furthermore, when comparing the minoxidil group with the clove oil group, the latter group exhibited a significant increase in the anagen/telogen ratio ($p = 0.000$), as illustrated in Table 2.

Table 2: Effect of Treatments on Anagen/Telogen Ratio in Different Study Groups by Kruskal-Wallis's test and the Dunn test

Groups (Mean \pm SD)	Induced Alopecia (1.9 \pm 0.5)	Minoxidil 5% (4.2 \pm 0.9)
Normal Control (3.4 \pm 0.6)	$P = 0.000^{**}$	-----
Minoxidil 5% (4.2 \pm 0.9)	$P = 0.000^{***}$	-----
Clove Oil 10% (6.1 \pm 0.8)		$P = 0.000^{***}$

Clove oil enhances follicular density in testosterone-induced androgenic alopecia: The study of dorsal skin tissue lysate showed a substantial decrease in follicular density in the group treated with testosterone compared to the normal group ($P = 0.000$). However, clove oil did not have a

significant effect on the follicular density content of the dorsal cutaneous tissue compared to minoxidil ($p = 0.898$). On the other hand, minoxidil considerably enhanced the follicular density compared to the induced group ($p = 0.000$). As illustrated in Table 3.

Table 3: Effect of Treatments on Follicular Density in Different Study Groups by Kruskal-Wallis's test and the Dunn test

Groups (Mean \pm SD)	Induced Alopecia (2.2 \pm 0.6)	Minoxidil 5% (5.8 \pm 0.9)
Normal Control (4.4 \pm 0.7)	$P = 0.000^{***}$	-----
Minoxidil 5% (5.8 \pm 0.9)	$P = 0.000^{***}$	-----
Clove Oil 10% (5.9 \pm 1.0)	-----	$P = 0.898$

Clove oil improves the histopathological picture in testosterone-induced androgenic alopecia: The Dorsal skin tissue sections stained with H & E showed significant damage to the hair follicle structure in the dorsal skin tissue of animals in the testosterone-induced group. This group exhibited a dermal layer with small and scattered hair follicles, which was more severe compared to the normal group of animals. The normal group maintained a normal dorsal skin architecture with a higher number of hair follicles accumulated deeper in the dermal layer of the skin. In contrast, the groups that were

treated with minoxidil (standard treatment) and clove oil were able to enhance the structure of the skin tissue on the back by increasing the number of hair follicles. Besides, in the minoxidil group, these new hair follicles were observed to form clusters, while in the clove oil group, they were arranged horizontally in a significantly higher quantity Figure 3. In this figure, the results are reported as the mean \pm SD, with a sample size of 8. The significance level was established at a threshold of $P < 0.05$. * ($P \leq 0.01$), ** ($P \text{ value} \leq 0.001$), and *** ($P \leq 0.0001$).

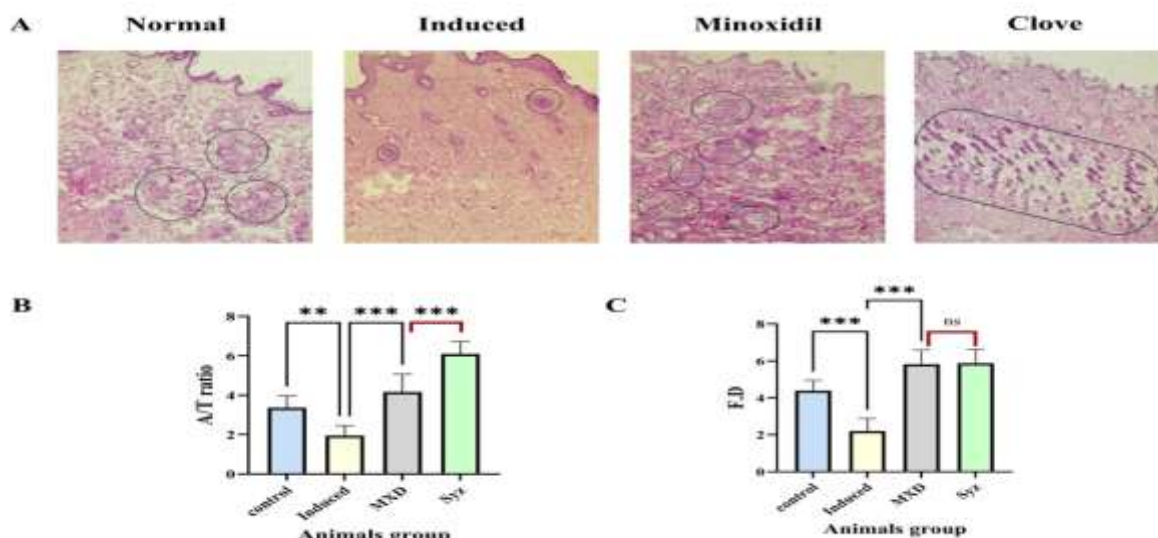


Figure 3: Histopathological results for Clove oil and hair growth in testosterone-induced Androgenic alopecia
A) Dorsal skin tissues stained with H&E (100X), **B)** changes in anagen/telogen ratio phases in the dorsal skin, **C)** changes in follicular density of the dorsal skin

Abbreviation: A/T: anagen/telogen ratio, MXD: minoxidil, Syz: *Syzygium aromaticum*, FD: follicular density, (Circled and enclosed = hair follicles).

Discussion:

The delivery of testosterone to the experimental mice resulted in a significant decrease in the hair follicular density and the ratio of anagen/telogen in comparison to the control group. These results confirm the effectiveness of the androgenic alopecia induction in the model (19). With this degree of alopecia our study evaluated the impact of *Syzygium aromaticum* therapy, and indicated that treatment with *Syzygium aromaticum* extract significantly enhanced the follicular density and the anagen/telogen ratio in comparison to the minoxidil-treated group. *Syzygium aromaticum* hair growth-promoting effects can be attributed to the chemical composition, which includes many active compounds such as flavonoids, terpenoids, and polyphenols (20). These components possess anti-inflammatory and antioxidant properties that are essential for facilitating hair development and mitigating hair loss. (21,22). The antioxidant properties of *Syzygium aromaticum* extract may safeguard the follicles from oxidative stress, which significantly contributes to hair loss. Furthermore, the anti-inflammatory effect of the extract may diminish inflammation in the hair follicles, resulting in enhanced follicle health and hair growth (23,24). Furthermore, certain bioactive components in *Syzygium aromaticum* extract may interact with androgen receptors or inhibit the 5- α reductase enzyme, which facilitates testosterone-to-DHT conversion (25,26). the complex pathophysiology of human androgenic alopecia. Therefore, future studies employing other models as part of the scalp or hair follicle of human culture, is essential in corroborating the promotion effect of *Syzygium aromaticum* on the hair follicle. In future research,

the primary focus should be on elucidating the mechanisms by which *Syzygium aromaticum* promotes the growth of hair. To do this, it may be necessary to investigate its influence on the stem cells of hair follicles, the cells of the dermal papilla, and the gene expression that are connected with the regulation of hair formation.

Conclusion:

Syzygium aromaticum oil may have a significant hair growth and antiandrogenic effect in mice with androgenic alopecia, which may be ascribed to its content of saponins, terpenoids, and steroids, leading to enhancement of the follicular density and an improvement of the anagen/telogen ratio. Future studies are recommended to address its viability as a therapy for androgenic alopecia, to comprehend the fundamental processes, and to assess its safety.

Limitations:

The employment of an animal model (BALB/c mice) constrains the direct relevance of the findings to humans owing to physiological disparities in hair growth cycles, hormone metabolism, and skin architecture.

Authors' declaration:

We confirm that all the Figures and Tables in the manuscript belong to the current study. Authors sign on ethical consideration's approval-Ethical Clearance: The project was approved by the local ethical committee in College of Medicine, University of Baghdad according to the code number (03-21) on (12/ 5/ 2024)

Conflicts of Interest: None

Funding: None

Authors' Contributions

Study conception & design: (Banan A. Mohammed, Huda I. Qasim). Literature search: (Banan A. Mohammed, Huda I. Qasim). Data acquisition: (Banan A. Mohammed, Huda I. Qasim). Data analysis & interpretation: (Banan A. Mohammed, Huda I. Qasim). Manuscript preparation: (Banan A. Mohammed, Huda I. Qasim). Manuscript editing & review: (Banan A. Mohammed, Huda I. Qasim).

References

1. Barkauskaite R, Serapinas D. Therapeutic implications of psychological state in patients with alopecia areata: A qualitative study. *Dermatol Ther [Internet]*. 2020 Nov 15;33(6):e14269. <https://doi.org/10.1111/dth.14269>
2. Fadheel BM. Clinico-Epidemiological Aspects of Telogen Effluvium in Iraqi Women. *J Fac Med Baghdad*. 2016;58(3):264-266. <https://doi.org/10.32007/jfacmedbagdad.583261>
3. Alessandrini A, Bruni F, Piraccini BM, Starace M. Common causes of hair loss-clinical manifestations, trichoscopy and therapy. *J Eur Acad Dermatology Venereol*. 2021;35(3):629-240. <https://doi.org/10.1111/jdv.17079>
4. Allawi AA. Prevalence Of Hypothyroidism In Chronic Kidney Disease Among Sample Of Iraqi Patients. *J Fac Med Baghdad*. 2013;55(2):97-101. <https://doi.org/10.32007/jfacmedbagdad.552631>
5. Ntshingila S, Oputu O, Arowolo AT, Khumalo NP. Androgenetic alopecia: An update. *JAAD Int [Internet]*. 2023 Dec;13:150-158. <https://doi.org/10.1016/j.jdin.2023.07.005>
6. Qader AA, Rasheed NW. Procaspace- 3 Status in Benign Prostatic Hyperplasia and Carcinoma (A Correlative Retrospective Study). *J Fac Med Baghdad [Internet]*. 2009 Oct 1;51(3):316-319. <https://doi.org/10.32007/jfacmedbagdad.5131134>
7. Waleed S, Taha ATM, Uthman AT. Effect of Salivary Melatonin on Ionizing Radiation Worker and its Effect on Periodontal Disease. *J Fac Med Baghdad*. 2024;66(1):79-84. <https://doi.org/10.32007/jfacmedbagdad.6612183>
8. Tan PC, Zhang PQ, Xie Y, Gao YM, Li QF, Zhou SB, et al. Autologous Concentrated Growth Factors Combined with Topical Minoxidil for the Treatment of Male Androgenetic Alopecia: A Randomized Controlled Clinical Trial. *Facial Plast Surg Aesthetic Med [Internet]*. 2021 Aug 1;23(4):255-262. <https://doi.org/10.1089/fpsam.2020.0288>
9. Begum A, Sain M, Singh A. Bioactive Compounds in Clove. In: *Spice Bioactive Compounds*. CRC Press; 2022. p. 137-164. <https://doi.org/10.1201/9781003215387-8>
10. Omran RH, Zahra'a AA, Alrawi AA. Evaluation of Some New Cytokines in Rheumatoid Arthritis. *J Fac Med Baghdad*. 2022;64(3):159-162. <https://doi.org/10.32007/jfacmedbagdad.6431963>
11. Leary S, Underwood W, Anthony R, Cartner S, Grandin T, Greenacre C, et al. AVMA Guidelines for the Euthanasia of Animals, 2020 ed. *Am Vet Med Assoc Schaumburg, IL, USA*. 2020;2002-2020.
12. Haro-González JN, Castillo-Herrera GA, Martínez-Velázquez M, Espinosa-Andrews H. Clove essential oil (*Syzygium aromaticum* L. Myrtaceae): Extraction, chemical composition, food applications, and essential bioactivity for human health. *Molecules*. 2021;26(21):6387. <https://doi.org/10.3390/molecules26216387>
13. Hajhashemi V, Rajabi P, Mardani M. Beneficial effects of pumpkin seed oil as a topical hair growth promoting agent in a mice model. *Avicenna J phytomedicine*. 2019;9(6):499. <https://doi.org/10.22038/AJP.2019.13463>
14. Ghonemy S, Alarawi A, Bessar H. Efficacy and safety of a new 10% topical minoxidil versus 5% topical minoxidil and placebo in the treatment of male androgenetic alopecia: a trichoscopic evaluation. *J Dermatolog Treat*. 2021;32(2):236-241. <https://doi.org/10.1080/09546634.2019.1654070>
15. Kresnanto VA, Sugihartini N, Yuwono T. Physical properties and irritation index essential oil of clove (*Syzygium aromaticum*) in absorption base ointment with variation concentration. *Fundam Appl Sci Adv Technol*. 2016;1746(1):25-26. <https://doi.org/10.1063/1.4953959>
16. Meimeti E, Kafanas A, Pavlou P, Evangelatou A, Tsouparelou P, Kanellopoulos S, et al. Topical treatment of skin injury inflicted in mice by X-ray irradiation. *Skin Pharmacol Physiol*. 2018;31(4):175-183. <https://doi.org/10.1159/000487404>
17. Rutin S, Chanprapaph K, Pakornphadungsit K, Leerunyakul K, Visessiri Y, Srisont S, et al. Variation of Hair Follicle Counts among Different Scalp Areas: A Quantitative Histopathological Study. *Ski Appendage Disord [Internet]*. 2022;8(1):24-30. <https://doi.org/10.1159/000518434>
18. Masson-Meyers DS, Andrade TAM, Caetano GF, Guimaraes FR, Leite MN, Leite SN, et al. Experimental models and methods for cutaneous wound healing assessment. *Int J Exp Pathol*. 2020;101(1-2):21-37. <https://doi.org/10.1111/iep.12346>
19. Grymowicz M, Rudnicka E, Podfigurna A, Napierala P, Smolarczyk R, Smolarczyk K, et al. Hormonal Effects on Hair Follicles. *Int J Mol Sci [Internet]*. 2020 Jul 28;21(15):5342. <https://doi.org/10.3390/ijms21155342>
20. El-Saber Batiha G, Alkazmi LM, Wasef LG, Beshbishy AM, Nadwa EH, Rashwan EK. *Syzygium aromaticum* L. (Myrtaceae): Traditional Uses, Bioactive Chemical Constituents, Pharmacological and Toxicological Activities. *Biomolecules [Internet]*. 2020 Jan 30;10(2):202. <https://doi.org/10.3390/biom10020202>
21. Sugihartini N, Lestari G, Yuliani S. Anti-inflammatory Capacity of Clove Bud (*Syzygium*

- aromaticum) Essential Oil in O/W and W/O Creams. *Pharmaciana*. 2019;9(1):109-18. <https://doi.org/10.12928/pharmaciana.v9i1.10023>
22. Abdulrida R, Z. Abdul-Jalil T. Evaluation of the active constituents, Antioxidant, and Antimicrobial Activities of Iraqi *Euonymus japonicus* leaves using Ethyl Acetate Extract. *J Fac Med Baghdad*. 2023;65(2):109-15. <https://doi.org/10.32007/jfacmedbagdad.1991>
23. Ali BM, Ibrahim O. Antifungal activity of clove (*Syzygium aromaticum*) essential oil extract against induced topical skin infection by *Candida albicans* in mice in vivo. *Egypt J Hosp Med*. 2023;91(1):3855-61. <https://doi.org/10.21608/ejhm.2023.293468>
24. Al-Hassan AAH. Role of Pro-and Anti-Inflammatory Cytokines in Rheumatoid Arthritis: Correlation with Disease Activity. *J Fac Med Baghdad*. 2010;52(3):286-91. <https://doi.org/10.32007/jfacmedbagdad.523976>
25. Vartak A, Sonawane S, Alim H, Patel N, Hamrouni L, Khan J, et al. Medicinal and Aromatic Plants in the Cosmetics Industry. In: *Medicinal and Aromatic Plants of India Vol I*. Springer; 2022. p. 341-64. https://doi.org/10.1007/978-3-030-98701-5_12
26. Jaafar AM, Majeed BAA, Al-Rubaie HAM. mRNA in situ hybridization analysis of VEGF in chronic lymphocytic leukemia. *J Fac Med Baghdad*. 2011;53(2). <https://doi.org/10.32007/jfacmedbagdad.532868>

How to Cite this Article

Abdul Ghany B, Qasim HI. Hair Growth Stimulating Effect of *Syzygium Aromaticum* in Testosterone-Induced Alopecia in A Mouse Model. *J Fac Med Baghdad* [Internet]. [cited 2025 May 27];. Available from: <https://iqjmc.uobaghdad.edu.iq/index.php/19JFacMedBaghdad36/article/view/2977>

تحفيز نمو الشعر في الفئران المصابة بالثعلبة الناتجة عن هرمون التستوستيرون: دراسة مقارنة بين زيت القرنفل الموضعي 10% ومينوكسيديل الموضعي 5%

بنان عبد الغني محمد¹، هدى إبراهيم قاسم¹
فرع الفارماكولوجي، كلية الطب، جامعة بغداد، بغداد، العراق.

الخلاصة:

الخلفية: يميز تدهور بصيالات الشعر الثعلبة الأندروجينية (AGA). يقصر هذا التدهور طور النمو ويطلق طور التيلوجين، محولا الشعر النهائي إلى شعر زغبي. يعاني الرجال والنساء من هذا المرض الشائع. يمكن لنبات السيزيجيوم العطري (*Syzygium aromaticum*) المضاد للبكتيريا والالتهابات ومضادات الأكسدة أن يعالجه..

الأهداف: دراسة مستخلص السيزيجيوم العطري كمعزز لنمو الشعر في حالات الصلع الناتج عن هرمون التستوستيرون، كبديل للعلاجات التقليدية ذات الآثار الجانبية الأقل.

الطريقة: أجريت دراسة تجريبية محكمة على الحيوانات في كلية الصيدلة بجامعة بغداد، من نوفمبر 2022 إلى ديسمبر 2024، لدعم هذه الدراسة. استخدمت فئران BALB/c ذكور بوزن يتراوح بين 25 و30 جراما، وتراوح أعمارها بين 8 و12 أسبوعا. غالبا ما يستخدم مينوكسيديل 5% (0.1 مل) لعلاج الثعلبة. عولجت الثعلبة بزيت سيزيجيوم أروماتيكوم 10% (0.8 مل). تسبب محلول هرمون التستوستيرون 5% (100 ميكرو لتر) في الصلع لدى الفئران. تم توزيع أربع مجموعات من ثمانية حيوانات عشوائيا: لم يعط أي علاج للمجموعة الأولى (المجموعة الضابطة السلبية) بعد حلاقة شعر الظهر. تلقت المجموعة الثانية (المجموعة الضابطة للثعلبة) 5% فقط من هرمون التستوستيرون. تلقت المجموعة الثالثة (مجموعة مينوكسيديل) 5% من هرمون التستوستيرون و5% من مينوكسيديل. المجموعة الرابعة (مجموعة زيت القرنفل) حصلت على 5% من هرمون التستوستيرون و10% من زيت القرنفل العطري.

النتائج: في المجموعة الثانية، تسبب تساقط الشعر الناتج عن التستوستيرون في انخفاضات كبيرة في نسبة طور النمو/طور الراحة (A/T) (1.12 ± 0.09) وكثافة الجريبات (0.5 ± 4.8 بصيلة/حقل) مقارنة بمجموعة التحكم (المجموعة الأولى: 0.24 ± 3.91؛ 0.7 ± 10.2). وبالمقارنة بالمجموعة المستحثة، أدى علاج مينوكسيديل بنسبة 5% (المجموعة الثالثة) إلى زيادة كبيرة في نسبة طور النمو/طور الراحة (0.20 ± 3.56، P < 0.0001) وكثافة الجريبات (0.6 ± 9.5، P < 0.0001). وأظهرت مجموعة علاج زيت القرنفل الرابعة تحسنا كبيرا في نسبة طور النمو/طور الراحة (0.18 ± 3.32، P < 0.0001)، ولكن كانت كثافة الجريبات القابلة للمقارنة (0.9 ± 8.8) مع مينوكسيديل غير ذي دلالة إحصائية. (P = 0.898). وقد أبد علم الأنسجة هذه النتائج، حيث أظهر أن مجموعتي المينوكسيديل وزيت القرنفل تمتعا بعدد بصيالات أعلى وبنية بصيالات أفضل، حيث كانت الأولى أكثر تكتلا والثانية أكثر أفقية.

الاستنتاج: يمكن استبدال علاجات الصلع الأندروجيني بمستخلص السيزيجيوم العطري. ويحتاج هذا المستخلص إلى تجارب بشرية لإثبات فعاليته وسلامته.

الكلمات المفتاحية: الصلع الأندروجيني؛ الشعر؛ مينوكسيديل؛ السيزيجيوم العطري؛ التستوستيرون.